

Radio-frequency Catheter Ablation of Atypical Atrioventricular Nodal Reentrant Tachycardia from a Trans-Aortic Approach

Ito, Koji

Department of Cardiovascular Medicine, Kyushu University Hospital

Takemoto, Masao

Department of Cardiovascular Medicine, Kyushu University Hospital

Mukai, Yasushi

Department of Cardiovascular Medicine, Kyushu University Hospital

Inoue, Shujiro

Department of Cardiovascular Medicine, Kyushu University Hospital

他

<https://doi.org/10.15017/16841>

出版情報：福岡醫學雜誌. 100 (12), pp.360-366, 2009-12-25. 福岡医学会
バージョン：
権利関係：

Case Report

Radio-frequency Catheter Ablation of Atypical Atrioventricular Nodal Reentrant Tachycardia from a Trans-Aortic Approach

Koji ITO¹⁾, Masao TAKEMOTO¹⁾, Yasushi MUKAI¹⁾, Shujiro INOUE¹⁾, Yoshikazu KAJI²⁾,
Akiko CHISHAKI¹⁾ and Kenji SUNAGAWA¹⁾

¹⁾*Department of Cardiovascular Medicine, Kyushu University Hospital, Fukuoka, Japan, and,*
²⁾*PS Clinic, Fukuoka, Japan.*

Abstract Radio-frequency catheter ablation (RFCA) was introduced for the treatment of reentrant tachyarrhythmias and has proven its usefulness, efficacy, and safety. It has gained the position of an early stage treatment option rather than being a 'last resort' option for certain groups of patients with supraventricular tachycardias including atrioventricular nodal reentrant tachycardia (AVNRT). The RFCA technique for AVNRT seems to have become established throughout these years and the right-side approach is considered to be the conventional method. However, in one percent of the patients with AVNRT it has been reported that they cannot be cured by the conventional method and a left-sided approach has been recommended. We experienced a case which presented with a fast/slow atypical AVNRT. We ultimately successfully treated the case with a left-sided (trans-aortic) RFCA approach. We believe the trans-aortic RFCA approach is a necessary alternative in the case of an unsuccessful RFCA via the right-sided approach even though the frequency of its need is very low.

Key words : Radio-frequency catheter ablation, AVNRT, Trans-Aortic approach

Introduction

The slow pathway (SP) conduction, which is usually located at the lower portion of Koch's triangle in the posteroseptal right atrium (RA), is a treatment target site for the radio-frequency (RF) catheter ablation (RFCA) of atrioventricular (AV) nodal (AVN) reentrant tachycardia (AVNRT), and it can achieve a very high success rate¹⁾²⁾. However, in about 1% of those patients with AVNRT, the SP conduction can not be ablated by RFCA from a conventional right-side approach¹⁾³⁾. Here we report a case of a fast/slow atypical AVNRT which required RFCA from a trans-aortic approach in order to ablate the SP of the AVN.

Case Presentation

A 20-year-old man was admitted to our hospital with a chief complaint of palpitations. A sustained narrow QRS complex tachycardia with a long RP' interval and heart rate of 180 bpm, which suddenly begun and terminated was documented by 24-h Holter monitoring (Fig. 1A). The electrocardiogram (ECG) (Fig. 1B), echocardiogram, and chest X-ray on admission were all normal.

An electrophysiological study (EPS) was performed to elucidate the mechanism of this narrow QRS tachycardia. Two multipolar electrode catheters were placed percutaneously in the coronary sinus (CS) and high RA, and His-bundle (HB) and right ventricle (RV), respectively (Fig. 2A). A multielectrode array catheter (EnSite 6.0J ; St. Jude Medical, Tokyo, Japan) was positioned in the RA (Fig. 2A). During sinus

Correspondence to :
Masao TAKEMOTO, M.D. Ph.D.
Department of Cardiovascular Medicine, Kyushu University Hospital,
3-1-1 Maidashi, Higashi-ku, Fukuoka 812-8582, Japan.
phone : + 81-92-642-5360 fax : + 81-92-642-5374
E-Mail : matakemo@cardiol.med.kyushu-u.ac.jp

rhythm, the intracardiac ECG revealed normal AH and HV intervals (Fig. 3A).

During RV pacing from 100 to 180 ppm, the site of the earliest atrial activation shifted from the HB region of the anterior septum to the CS ostium (CSos) (Fig. 3BC) probably associated with a shift from the retrograde conduction over the fast pathway (FP) to that over the slow pathway (SP). The ventriculoatrial (VA) Wenckebach cycle length was 300 milliseconds. During RV (closed circles in Fig. 4A) or RA (closed circles in Fig. 4B) extra stimulation at a pacing cycle length of 500 milliseconds, retrograde or antegrade AVN decremental conduction was revealed. Furthermore, although no obvious evidence of an antegrade dual AVN pathway could be confirmed, a retrograde dual AVN pathway was revealed by the findings of a 66 milliseconds increase in the VA interval with atrial echo beats following the shortening of the V1-V2 interval from 440 to 430 milliseconds (Fig. 3D and 4AB). However, the clinical narrow QRS tachycardia could not be sustained even under the intravenous administration of isoproterenol. The retrograde AVN conduction was completely abolished by an

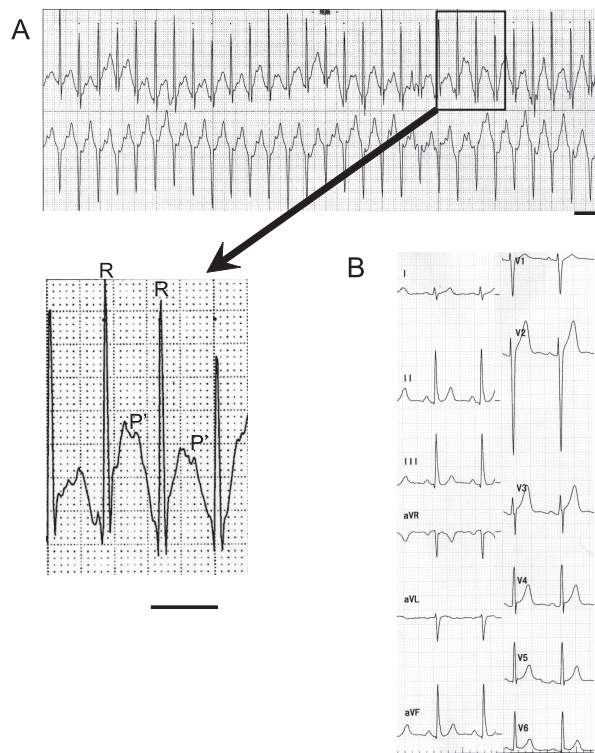


Fig. 1 The 24-h Holter monitoring during the narrow QRS complex tachycardia with a long RP interval and a heart rate of 180 bpm (panel A), and the 12-lead electrocardiogram on admission (panel B). The bars indicate 400 milliseconds.

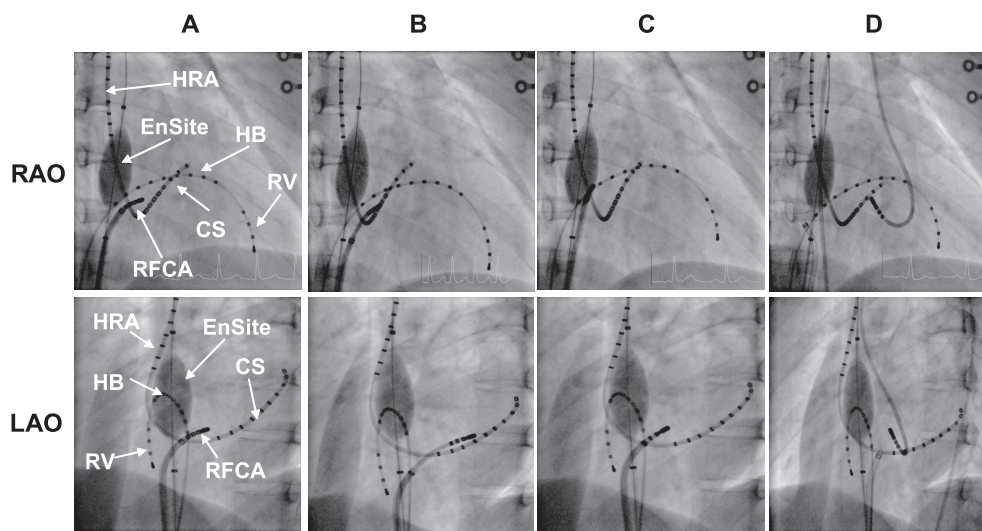


Fig. 2 Fluoroscopic images in the right (RAO; upper panels) and left (LAO; lower panels) anterior oblique views showing the location of the multipolar electrode catheters and a radiofrequency ablation catheter (RFCA) placed in the high right atrium (HRA), His-bundle (HB), proximal coronary sinus (CSp), coronary sinus (CS), and right ventricle (RV) during the RF energy delivering between the tricuspid annulus and inside of the CS ostium (CSos) (panels A and B), to the RA side of the interatrial septum, posterior to the CSos (panel C), and to the left atrial side of the interatrial septum at the mitral annular level using a retrograde trans-aortic approach (panel D), respectively.

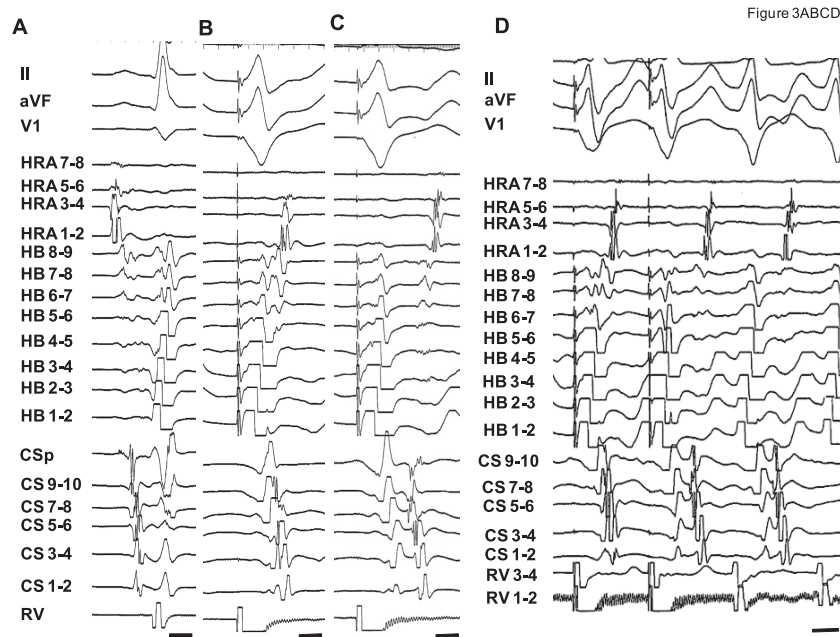


Fig. 3 The intracardiac recordings during sinus rhythm (panel A) revealing the activation sequence in the high right atrium (HRA), His-bundle (HB), proximal coronary sinus (CSp), coronary sinus (CS), and right ventricle (RV), with normal AH and HV intervals. The intracardiac recordings during right ventricular (RV) rapid pacing from 100 to 180 ppm revealing that the site of the earliest atrial activation had shifted from the HB (panel B) to the CSOs (panel C) during and after the second RV pacing episode, and was associated with a shift from the retrograde conduction over the fast pathway to that over the slow pathway (SP). A retrograde dual atrioventricular nodal pathway was revealed with the findings of a 66 millisecond increase in the VA interval with atrial echo beats following the shortening of the V1-V2 interval from 440 to 430 (panel D) milliseconds. The bars indicate 100 milliseconds.

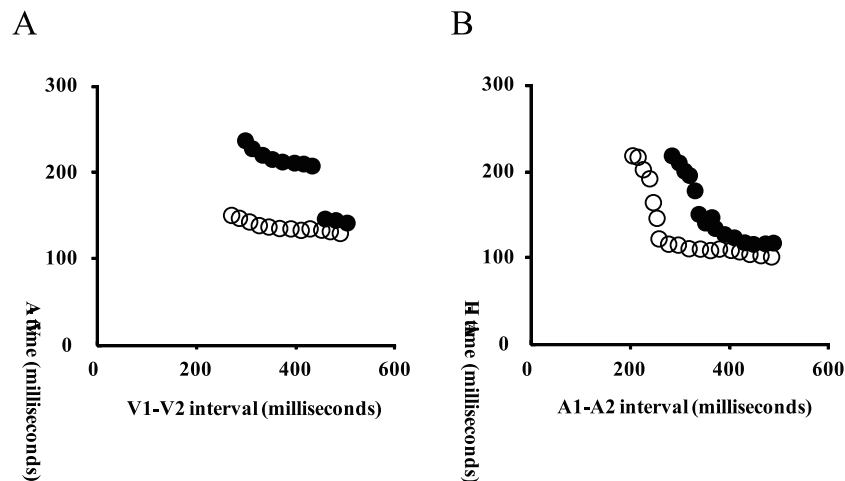


Fig. 4 During RV (panel A) or HRA (panel B) extra stimulation at a pacing cycle length of 500 milliseconds, the retrograde or antegrade atrioventricular nodal (AVN) decremental conduction was revealed. Although no obvious evidence of an antegrade dual AVN pathway could be confirmed (panel B), a retrograde dual AVN pathway was revealed by the findings of a 66 millisecond increase in the ventriculoatrial (VA) interval following the shortening of the V1-V2 interval from 440 to 430 milliseconds before the radio-frequency catheter ablation (RFCA) (●) (panel A). On the other hand, no evidence of an increase in the VA interval of more than 50 milliseconds following the shortening of the V1-V2 interval even under the intravenous administration of isoproterenol after RFCA (○) was observed (panel A).

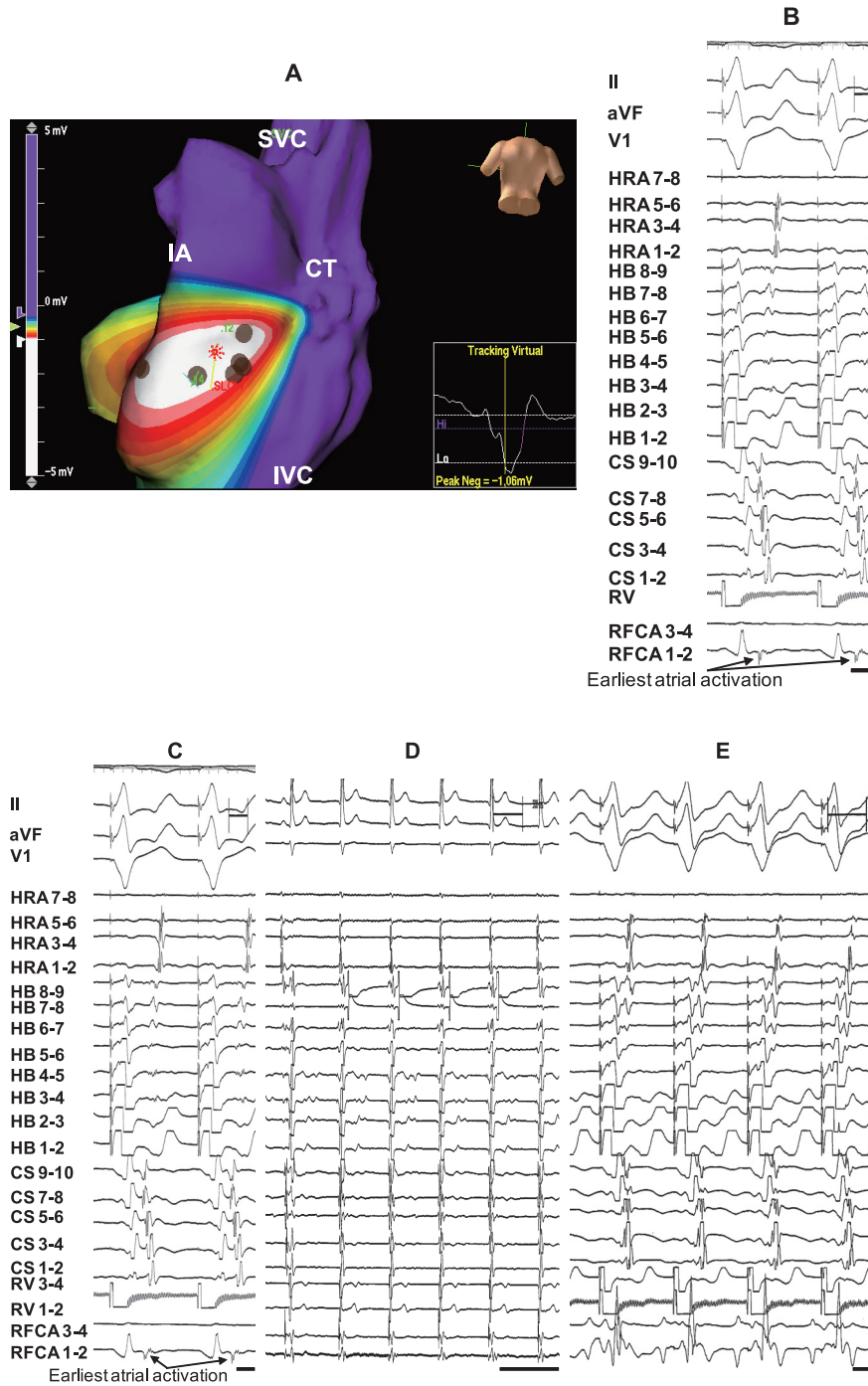


Fig. 5 An EnSite image of the right atrium in the postero-anterior view (panel A) and intracardiac recording (panel B) showing the earliest atrial activation over the slow pathway (SP) in the posterior region of the coronary sinus ostium of the right atrial side of the interatrial septum during right ventricle (RV) pacing. The intracardiac recordings during RV pacing (panel C) revealing the earliest atrial activation over the SP in the radio-frequency catheter (RFCA) recording placed on the left atrial side of the interatrial septum at the mitral annular level using a retrograde trans-aortic approach. An immediate accelerated junctional rhythm was revealed (panel D) during the RFCA at that site. No retrograde conduction over the SP could be confirmed during RV pacing from 110 to 200 ppm after the RFCA (panel E). The bars indicate 100 milliseconds. SVC; superior vena cava, IVC; inferior vena cava, IA; interatrium, CT; crista terminalis.

intravenous administration of 20 mg of adenosine. In view of these findings, we diagnosed this clinical narrow QRS tachycardia as a fast/slow form of atypical AVNRT¹⁴⁾. Therefore, RFCA of the SP of the AVN was performed.

First, the RF energy application (Ablaze 7Fr, 4 mm-tip, Japan Lifeline Co., Ltd., Tokyo, Japan) was delivered between the tricuspid annulus and inside of the CSos (Fig. 2AB), and to the RA side of the interatrial septum, posterior to the CSos (Fig. 2C), which were detected by conventional mapping or an EnSite system (Fig. 5AB) as the earliest atrial activation over the SP during RV pacing. Although an immediate accelerated junctional rhythm was revealed during repeated RF energy applications (30 watts, 50 degree Celsius) delivered there, the retrograde AVN conduction over the SP still existed. However, the VA Wenckebach cycle length slightly prolonged to 333 milliseconds. Next, an RF energy application was delivered to the left atrial side of the interatrial septum at the mitral annular level which was the earliest atrial activation, and was 4 milliseconds earlier than that in the right atrium, during RV pacing (Fig. 5C) using a retrograde trans-aortic approach (Fig. 2D). During repeated RF energy applications (30 watts, 50 degree Celsius) delivered there, an immediate accelerated junctional rhythm was revealed (Fig. 5D) and finally the SP of the AVN was successfully ablated. No retrograde conduction over the SP could be confirmed during RV pacing from 110 to 200 ppm (Fig. 5E), or by the findings of no increase in the VA interval following the shortening of the V1-V2 interval (open circles in Fig. 4B) of greater than 50 milliseconds even under the intravenous administration of isoproterenol. He has remained well without any symptoms for more than 2 year after the RFCA.

Discussion

An SP potential and accelerated junctional rhythm during the delivery of RF energy delivery are one of the sensitive markers that are well

correlated to a successful RFCA of AVNRT¹⁵⁾. During fast/slow AVNRT, the impulse commonly propagates down the FP in the anterior septum and up the SP in the posterior septum, with the earliest retrograde atrial activation occurring near the CSos¹⁾. Thus, an SP potential can be detected during the mapping, and an accelerated junctional rhythm should usually be induced during the RF energy delivery in that area.

In this present case, the earliest retrograde atrial activation site in the RA was detected between the tricuspid annulus and inside of the CSos using conventional mapping (Fig. 2AB), and in the posterior region of the CSos on the RA side of the interatrial septum with EnSite (Fig. 2C and 5AB). Moreover, an SP potential could also be detected (Fig. 5B) at those sites, and an immediate accelerated junctional rhythm was steadily observed during the delivery of the RF energy. However, RFCA at those sites from the right-sided approach could not completely ablate the SP. Previous studies have demonstrated that, in about 1% of the patients with AVNRT, the SP conduction could not be ablated by RFCA using a conventional right-side approach¹³⁾, and the SP may rarely be located in the CS1 or on the mitral annulus⁶⁾⁷⁾. These findings may indicate that the SP and accelerated junctional rhythm during the delivery of the RF energy may not be indicators of successful sites in this subgroup of the patients with AVNRT. Thus, we performed mapping on the left atrial side of the interatrial septum with a trans-aortic approach. Delivery of RF energy to the mitral annular level at the site recording the earliest atrial activation potential using a retrograde trans-aortic approach (Fig. 2D and 5C) resulted in an immediate accelerated junctional rhythm (Fig. 5D), and finally could readily ablate the SP of the AVN (Fig. 4 and 5E).

We suspect that, in this present case, the SP may have extended broadly⁸⁾ because of the finding of a slight prolongation of the VA Wenckebach cycle length from 300 to 333 milliseconds after the RF energy delivered from

right-sided approach. Thus, the potential recorded from the RA side may have represented a far-field recording of the activation on the left side of the septum.

To the best of our knowledge, there have been no reports on cases undergoing RFCA using a retrograde trans-aortic approach for fast/slow atypical AVNRT as in this present case. The frequency of the need to perform a trans-aortic approach to treat AVNRT may be extremely low⁷⁹⁾. However, mapping of the mitral annulus for an alternate ablation site for AVNRT from a trans-aortic approach should be considered when the conventional right-sided approach was ineffective.

Acknowledgements

We thank Ryoko Hayashi, Keiji Kobayashi, and Noriko Nakajima for their technical assistance with the electrophysiological study in the cardiac catheterization laboratory, and John Martin for his linguistic assistance with this paper.

References

- 1) Jackman WM, Beckman KJ, McClelland JH, Wang X, Friday KJ, Roman CA, Moulton KP, Twidale N, Hazlitt HA and Prior MI : Treatment of supraventricular tachycardia due to atrioventricular nodal reentry, by radiofrequency catheter ablation of slow-pathway conduction. *N Engl J Med* 327 : 313-318, 1992.
- 2) Haissaguerre M, Gaita F, Fischer B, Commenges D, Montserrat P, d'Ivernois C, Lemetayer P and Warin JF : Elimination of atrioventricular nodal reentrant tachycardia using discrete slow potentials to guide application of radiofrequency energy. *Circulation* 85 : 2162-2175, 1992.
- 3) Kose S, Amasyali B, Aytemir K, Kilic A, Can I, Kursaklioglu H, Celik T and Isik E : Atrioventricular nodal reentrant tachycardia with multiple discontinuities in the atrioventricular node conduction curve : immediate success rates of radiofrequency ablation and long-term clinical follow-up results as compared to patients with single or no AH-jumps. *J Interv Card Electrophysiol* 10 : 249-254, 2004.
- 4) Sung RJ, Waxman HL, Saksena S and Juma Z : Sequence of retrograde atrial activation in patients with dual atrioventricular nodal pathways. *Circulation* 64 : 1059-1067, 1981.
- 5) Thakur RK, Klein GJ, Yee R and Stites HW : Junctional tachycardia : a useful marker during radiofrequency ablation for atrioventricular node reentrant tachycardia. *J Am Coll Cardiol* 22 : 1706-1710, 1993.
- 6) Jaïs P, Haïssaguerre M, Shah DC, Coste P, Takahashi A, Barold SS and Clémenty J : Successful radiofrequency ablation of a slow atrioventricular nodal pathway on the left posterior atrial septum. *Pacing Clin Electrophysiol* 22 : 525-527, 1999.
- 7) Altemose GT, Scott LR and Miller JM : Atrioventricular nodal reentrant tachycardia requiring ablation on the mitral annulus. *J Cardiovasc Electrophysiol* 11 : 1281-1284, 2000.
- 8) Otomo K, Okamura H, Noda T, Satomi K, Shimizu W, Suyama K, Kurita T, Aihara N and Kamakura S : "Left-variant" atypical atrioventricular nodal reentrant tachycardia : electrophysiological characteristics and effect of slow pathway ablation within coronary sinus. *J Cardiovasc Electrophysiol* 17 : 1177-1183, 2006.
- 9) Kilic A, Amasyali B, Kose S, Aytemir K, Celik T, Kursaklioglu H, Iyisoy A, Ozmen N, Yuksel C, Lenk MK and Isik E : Atrioventricular nodal reentrant tachycardia ablated from left atrial septum: clinical and electrophysiological characteristics and long-term follow-up results as compared to conventional right-sided ablation. *Int Heart J* 46 : 1023-1031, 2005.

(Received for publication February 10, 2010)

(和文抄録)

左心からの通電が有効であった稀有型房室結節回帰性頻拍の一例

¹⁾九州大学病院循環器内科

²⁾相生会ピーエスクリニック

伊藤浩司¹⁾, 竹本真生¹⁾, 向井 靖¹⁾, 井上修二郎¹⁾,
加治良一²⁾, 樗木晶子¹⁾, 砂川賢二¹⁾

高周波カテテルアブレーション治療は、様々な頻拍性不整脈の重要な治療オプションとなっている。房室結節回帰性頻拍症に対してもカテテルアブレーション治療は、近年確立されたものになってきており、通常は右心アプローチにより行われている。しかし、1%の患者においては通常の右心アプローチでは焼灼できず、左心アプローチが有効である症例も報告されている。今回我々は、特に稀有型 (fast-slow) 房室結節回帰性頻拍症において左心からの通電が有効であった症例を経験した。

症例は20歳代男性。頻回の動悸を訴え、Holter心電図で症状と一致して心拍数180 bpmのnarrow QRS tachycardiaを認めた。12誘導心電図は正常で、心エコーも器質的心疾患は認めなかった。電気生理学的検査では通常とおり、高位右房(HRA)、ヒス束、右室(RV)、冠静脈洞(CS)に電極カテを留置した。またEnSite電極を右房内に留置した。RV頻拍刺激にて頻拍刺激~160 ppmではearliest retro A=His (fast pathway; FP)、160 ppm~でearliest retro A=CS開口部 (slow pathway; SP)の室房伝導を認めた。ATP 20mgで室房伝導の消失を認めた。RV期外刺激では室房時間は減衰伝導を認め、S1-S1=500ms, S1-S2=430 msで室房時間のjump upと2 echoを認めた。HRA期外刺激では、心房ヒス時間は減衰伝導を認めたが、jump upは認めなかった。イソプロテレノール投与下のプログラム刺激でもnarrow QRS tachycardiaは誘発されなかったが、上記所見よりfast-slowの稀有型房室結節回帰性頻拍と診断し、SPへの通電を行うこととした。まずABLカテテル (Fantasista)にてCS開口部近傍およびCS内をRV頻拍刺激下でマッピングを行い、最早期A波興奮部位にて数回通電を行ったが、junctional rhythmは出現するもののSPの焼灼には至らなかった。さらにRV頻拍刺激下でEnSiteにてマッピングを行いSPのRAへのbreakout pointの同定を行った後に同部位で数回通電を行ったが、junctional rhythmは出現するもののやはりSPの焼灼には至らなかった。心筋深部あるいは左心側のSPの存在を考え、経大動脈アプローチにて僧帽弁輪上中隔寄りにて通電を行ったところ、SPを介する室房伝導は消失しその後再発を認めなかった。さらに、RV期外刺激での室房時間のjump upの消失も認めた。SPの走行のvariationは多数報告されているが、本症例は稀有型房室結節回帰性頻拍症において左心からの通電を必要とした非常に稀有な症例と考えられ考察を加えて報告する。